

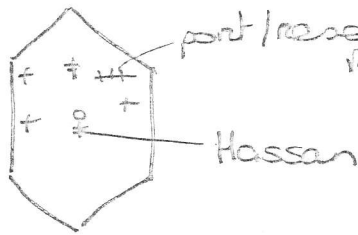
OPERATION CHART

SURGEON'S NOTES

Operation Performed

Laparoscopy, washout
 removal of Gastric band.

Surgeon: Prof. Conlon
 Assistant: H. O'Grady, K. Browne
 Nurses.....
 Anaesthetist.....



port/reservoir removed. Findings: omentum
 adherent to falciform ligament
 Bluntly dissected free
 - subdiaphragmatic collection,
 Subhepatic & perigastric collection
 aspirated.
 - Gastric band device removed.
 - Fundoplication sutures removed.

OGD → Gastritis + Acute ulcers (small)
 Good gastric distension.
 No obvious air leak.

Washout - 2 litres.

3 Robinsons drains - subdiaphragmatic
 - subhepatic
 - perigastric.

closure: 1 vicryl
 clips.

Post op: NG tube on suction
 IV Antibiotics - Augmentin / Flagyl / Gent

Drain Inserted Yes / No
 +3

Specimen to Lab. Yes / No
 Micro

Date: 31. 10. 06.

Signature: H. O'Grady